

Japanese classification of gastric carcinoma: 3rd English edition

Japanese Gastric Cancer Association

Published online: 15 May 2011

© The International Gastric Cancer Association and The Japanese Gastric Cancer Association 2011

1 General principles

Gastric cancer findings are categorized and recorded using the upper case letters T, H, etc. The extent of disease for each parameter is expressed by Arabic numerals following the letter (e.g., T3 H1); where the extent of disease is unknown, X is used. The clinical and pathological classifications are derived from information acquired from various clinical, imaging, and pathological sources (listed in Table 1). The clinical classification (c) is derived at the conclusion of pretreatment assessment before a decision is made regarding the appropriateness of surgery. This classification is an essential guide to treatment selection and enables the evaluation of therapeutic options. The pathological classification (p) is based on the clinical classification supplemented or modified by additional evidence acquired from pathological examination. This informs decision-making regarding additional therapy and provides prognostic information. Where there is doubt regarding the T, N, or M category, the less advanced category should be used.

Histological tumor findings are recorded in the following order: tumor location, macroscopic type, size, histological type, depth of invasion, cancer–stroma relationship, pattern of infiltration, lymphatic invasion, venous invasion, lymph node metastasis, and resection margins. For example: L, Less, Type 2, 50 × 20 mm, tub1 > tub2, pT2, int, INFb, ly1, v1, pN1 (2/13), pPM0, pDM0 (see subsequent text for an explanation of the abbreviations).

2 Anatomical extent and stage of gastric carcinoma

2.1 Description of the primary tumor

2.1.1 Size and number of lesions

The two greatest dimensions should be recorded for each lesion. Where there are multiple lesions, the tumor with the most advanced T category (or the largest lesion where the T stage is identical) is classified.

2.1.2 Tumor location

2.1.2.1 The three gastric regions and the esophagogastric junction The stomach is anatomically divided into three portions, the upper (U), middle (M), and lower (L) parts, by the lines connecting the trisected points on the lesser and greater curvatures (Fig. 1). Gastric tumors are described by the parts involved. If more than one part is involved, all involved portions should be recorded in descending order of degree of involvement, with the part containing the bulk of tumor first, e.g., LM or UML. Tumor extension into the esophagus or duodenum is recorded as E or D, respectively.

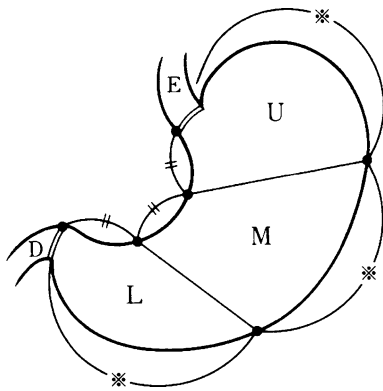
The online version of the prefatory article referred to in this article can be found under doi:10.1007/s10120-011-0040-6.

English edition editors: Takeshi Sano (✉), Yasuhiro Kodera.
e-mail: takeshi.sano@jgca.or.jp

Japanese Gastric Cancer Association (✉)
Association office, First Department of Surgery,
Kyoto Prefectural University of Medicine,
Kawaramachi, Kamigyo-ku, Kyoto 602-0841, Japan
e-mail: jgca@koto.kpu-m.ac.jp

Table 1 Clinical and pathological classification

Clinical classification (c)	Pathological classification (c)
Physical examination, imaging studies, endoscopic, laparoscopic and surgical findings, biopsy, cytology, biochemical and biological investigations.	Histological examination of surgically or endoscopically resected specimens; peritoneal lavage cytology.

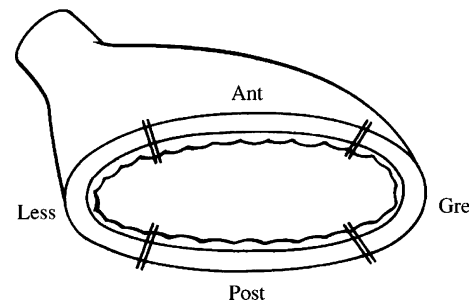
**Fig. 1** The three portions of the stomach. *U* upper third, *M* middle third, *L* lower third, *E* esophagus, *D* duodenum

The area extending 2 cm above to 2 cm below the esophagogastric junction (EGJ) is designated the EGJ area. Tumors having their epicenter in this area are designated EGJ carcinomas irrespective of histological type. The location of an EGJ carcinoma is described using the symbols E (proximal 2 cm segment) and G (distal 2 cm segment), with the dominant area of invasion described first, i.e., E, EG, E=G (both areas equally involved), GE, or G. The distance between the tumor center and the EGJ is recorded.

The EGJ is defined as the border between the esophageal and gastric muscles. Clinically this is identified by one of the following: (a) the distal end of the longitudinal palisading small vessels in the lower esophagus at endoscopy; (b) the horizontal level of the angle of His shown by barium meal examination; (c) the proximal end of the longitudinal folds of the greater curve of the stomach shown at endoscopy or barium meal study; or (d) the level of the macroscopic caliber change of the resected esophagus and stomach. It is important to note that the squamocolumnar junction (SCJ) does not always coincide with the EGJ.

Clinically, the tumor location is often expressed as cardia, fundus, body, incisura, and antrum.

2.1.2.2 Cross-sectional parts of the stomach The stomach's cross-sectional circumference is divided into four equal parts: the lesser (Less) and greater (Gre) curvatures, and the anterior (Ant) and posterior (Post) walls (Fig. 2). Circumferential involvement is recorded as Circ.

**Fig. 2** The four equal parts of the gastric circumference. *Less* lesser curvature, *Gre* greater curvature, *Ant* anterior wall, *Post* posterior wall

2.1.2.3 Carcinoma in the remnant stomach Carcinoma in the remnant stomach encompasses all carcinomas arising in the remnant stomach following a gastrectomy, irrespective of the histology of the primary lesion (benign or malignant) or its risk of recurrence, the extent of resection, or method of reconstruction. The following information should be recorded, as well as, if available, information on the extent of resection and type of reconstruction of the previous gastrectomy.

- The primary lesion at the previous gastrectomy: benign (B), malignant (M), or unknown (X).
- The time interval elapsed between the previous gastrectomy and the current diagnosis, in years (unknown: X).
- Tumor location in the remnant stomach: anastomotic site (A), gastric suture line (S), other gastric site (O), or total remnant stomach (T). Extension into the esophagus (E), duodenum (D), or jejunum (J) is recorded.

Examples: B-20-S, M-09-AJ.

2.1.3 Macroscopic types

2.1.3.1 Basic classification Gross tumor morphology is categorized as either superficial or advanced type. Superficial type is typical of T1 tumors while T2–4 tumors usually manifest as advanced types (Fig. 3). Viewed from the mucosal surface, gross tumor appearance is categorized into six types (Table 2). Type 0 is subdivided according to the Macroscopic Classification of Early Gastric Cancer (Sect. 2.1.3.2). Although macroscopic type is determined regardless of the depth of tumor invasion, the T category should also be recorded.

2.1.3.2 Subclassification of Type 0 (Fig. 4, modified from the Japanese Endoscopy Society Classification of 1962) Superficial tumors with two or more components should have all components recorded in order of the surface area occupied, e.g. 0-IIc + III (Table 3).

2.1.3.3 Description of macroscopic type The macroscopic tumor type should be recorded in both the clinical and pathological classifications.

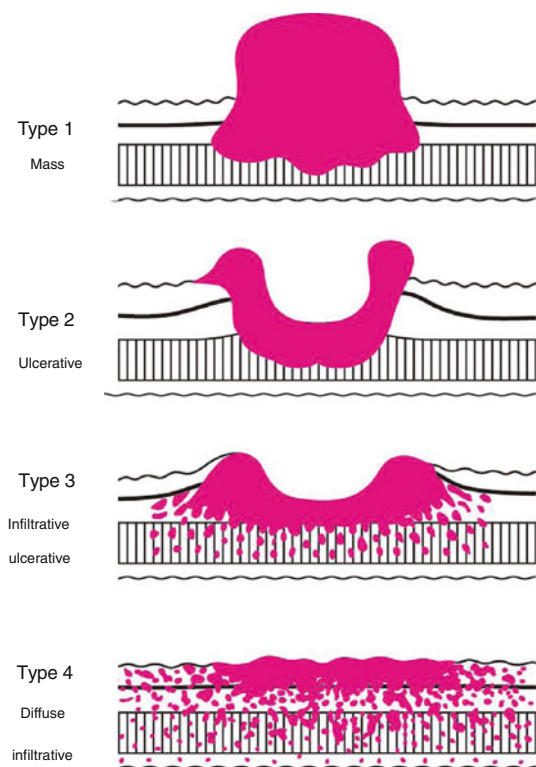


Fig. 3 Macroscopic types of advanced gastric cancer

Table 2 Macroscopic types

Type 0 (superficial)	Typical of T1 tumors.
Type 1 (mass)	Polypoid tumors, sharply demarcated from the surrounding mucosa.
Type 2 (ulcerative)	Ulcerated tumors with raised margins surrounded by a thickened gastric wall with clear margins.
Type 3 (infiltrative ulcerative)	Ulcerated tumors with raised margins, surrounded by a thickened gastric wall without clear margins.
Type 4 (diffuse infiltrative)	Tumors without marked ulceration or raised margins, the gastric wall is thickened and indurated and the margin is unclear.
Type 5 (unclassifiable)	Tumors that cannot be classified into any of the above types.

2.1.4 Histological classification (Table 4)

Where a malignant epithelial tumor consists of more than one histological subtype, the different histological components should be recorded in descending order of the surface area occupied, e.g., tub 1 > pap (see table below).

2.1.5 Depth of tumor invasion (T)

The depth of tumor invasion is recorded as the T-category. Conventional characters denoting depth of tumor invasion

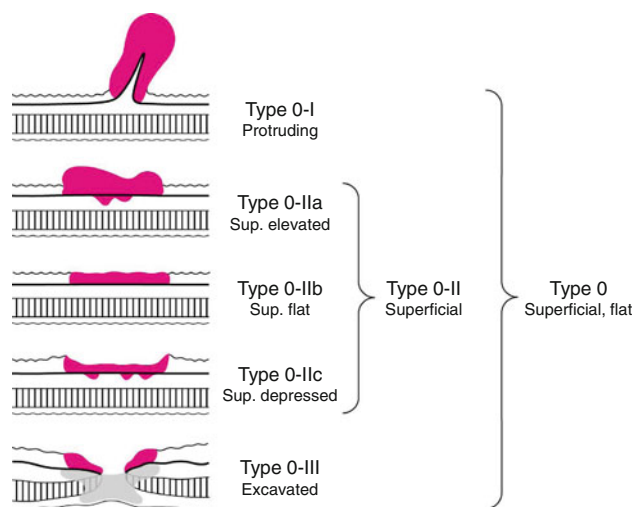


Fig. 4 Subclassification of Type 0

Table 3 Subclassification of Type 0

Type 0-I (protruding) ^a	Polypoid tumors.
Type 0-II (superficial)	Tumors with or without minimal elevation or depression relative to the surrounding mucosa.
Type 0-IIa (superficial elevated) ^a	Slightly elevated tumors.
Type 0-IIb (superficial flat)	Tumors without elevation or depression.
Type 0-IIc (superficial depressed)	Slightly depressed tumors.
Type 0-III (excavated)	Tumors with deep depression.

^a Tumors with less than 3mm elevation are usually classified as 0-IIa, with more elevated tumors being classified as 0-I

are also recorded: M, SM, MP, SS, SE, SI (see below). The prefixes “c” and “p” are used in conjunction with the T-category and not with the characters M, SM, etc. (e.g., a pathologically diagnosed mucosal tumor should be recorded as pT1a, not pM). Tumor invasion into the muscularis mucosa is included in the M category. Early gastric cancer comprises of T1 tumors irrespective of lymph node metastasis.

- TX Depth of tumor unknown
- T0 No evidence of primary tumor
- T1 Tumor confined to the mucosa (M) or submucosa (SM)
 - T1a Tumor confined to the mucosa (M)
 - T1b Tumor confined to the submucosa (SM)¹
- T2 Tumor invades the muscularis propria (MP)

¹ SM may be subclassified as SM1 or T1b1 (tumor invasion is within 0.5 mm of the muscularis mucosae) or SM2 or T1b2 (tumor invasion is 0.5 mm or more deep into the muscularis mucosae).

Table 4 Histological classification of gastric tumors

Benign epithelial tumor	ICD-O code
Adenoma	8140/0
Malignant epithelial tumor	
<i>Common type</i>	
Papillary adenocarcinoma (pap)	8260/3
Tubular adenocarcinoma (tub)	8211/3
Well-differentiated (tub1)	
Moderately differentiated (tub2)	
Poorly differentiated adenocarcinoma (por)	
Solid type (por1)	
Non-solid type (por2)	
Signet-ring cell carcinoma (sig)	8490/3
Mucinous adenocarcinoma (muc)	8489/3
<i>Special type</i>	
Carcinoid tumor	8240/3
Endocrine carcinoma	8401/3
Carcinoma with lymphoid stroma	
Hepatoid adenocarcinoma	
Adenosquamous carcinoma	8560/3
Squamous cell carcinoma	8070/3
Undifferentiated carcinoma	8020/3
Miscellaneous carcinoma	
Non-epithelial tumor	
Gastrointestinal stromal tumor (GIST)	8396/0,1,3
Smooth muscle tumor	8890/0,3
Neurogenic tumor	9560/9580/0
Miscellaneous non-epithelial tumors	
Lymphoma	
<i>B-cell lymphoma</i>	
MALT (mucosa-associated lymphoid tissue) lymphoma	9699/3
Follicular lymphoma	9690/3
Mantle cell lymphoma	9673/3
Diffuse large B-cell lymphoma	9680/3
Other B-cell lymphomas	
<i>T-cell lymphoma</i>	
<i>Other lymphomas</i>	
Metastatic tumor	
Tumor-like lesion	
Hyperplastic polyp	
Fundic gland polyp	
Heterotopic submucosal gland	
Heterotopic pancreas	
Inflammatory fibroid polyp (IFP)	
Gastrointestinal polyposis	
Familial polyposis coli, Peutz–Jeghers syndrome, juvenile polyposis, Cowden’s disease	
<i>Others</i>	

Table 5 Anatomical definitions of lymph node stations

No.	Definition
1	Right paracardial LNs, including those along the first branch of the ascending limb of the left gastric artery.
2	Left paracardial LNs including those along the esophagocardiac branch of the left subphrenic artery
3a	Lesser curvature LNs along the branches of the left gastric artery
3b	Lesser curvature LNs along the 2nd branch and distal part of the right gastric artery
4sa	Left greater curvature LNs along the short gastric arteries (perigastric area)
4sb	Left greater curvature LNs along the left gastroepiploic artery (perigastric area)
4d	Rt. greater curvature LNs along the 2nd branch and distal part of the right gastroepiploic artery
5	Suprapyloric LNs along the 1st branch and proximal part of the right gastric artery
6	Infrapyloric LNs along the first branch and proximal part of the right gastroepiploic artery down to the confluence of the right gastroepiploic vein and the anterior superior pancreaticoduodenal vein
7	LNs along the trunk of left gastric artery between its root and the origin of its ascending branch
8a	Anterosuperior LNs along the common hepatic artery
8p	Posterior LNs along the common hepatic artery
9	Celiac artery LNs
10	Splenic hilar LNs including those adjacent to the splenic artery distal to the pancreatic tail, and those on the roots of the short gastric arteries and those along the left gastroepiploic artery proximal to its 1st gastric branch
11p	Proximal splenic artery LNs from its origin to halfway between its origin and the pancreatic tail end
11d	Distal splenic artery LNs from halfway between its origin and the pancreatic tail end to the end of the pancreatic tail
12a	Hepatoduodenal ligament LNs along the proper hepatic artery, in the caudal half between the confluence of the right and left hepatic ducts and the upper border of the pancreas
12b	Hepatoduodenal ligament LNs along the bile duct, in the caudal half between the confluence of the right and left hepatic ducts and the upper border of the pancreas
12p	Hepatoduodenal ligament LNs along the portal vein in the caudal half between the confluence of the right and left hepatic ducts and the upper border of the pancreas
13	LNs on the posterior surface of the pancreatic head cranial to the duodenal papilla
14v	LNs along the superior mesenteric vein
15	LNs along the middle colic vessels
16a1	Paraortic LNs in the diaphragmatic aortic hiatus
16a2	Paraortic LNs between the upper margin of the origin of the celiac artery and the lower border of the left renal vein
16b1	Paraortic LNs between the lower border of the left renal vein and the upper border of the origin of the inferior mesenteric artery

Table 5 continued

No.	Definition
16b2	Para-aortic LNs between the upper border of the origin of the inferior mesenteric artery and the aortic bifurcation
17	LNs on the anterior surface of the pancreatic head beneath the pancreatic sheath
18	LNs along the inferior border of the pancreatic body
19	Infradiaphragmatic LNs predominantly along the subphrenic artery
20	Paraesophageal LNs in the diaphragmatic esophageal hiatus
110	Paraesophageal LNs in the lower thorax
111	Supradiaphragmatic LNs separate from the esophagus
112	Posterior mediastinal LNs separate from the esophagus and the esophageal hiatus
T3	Tumor invades the subserosa (SS)
T4	Tumor invasion is contiguous to or exposed beyond the serosa (SE) or tumor invades adjacent structures (SI)
T4a	Tumor invasion is contiguous to the serosa or penetrates the serosa and is exposed to the peritoneal cavity (SE) ²
T4b	Tumor invades adjacent structures (SI). ³

2.1.6 Cancer stromal volume, infiltrative pattern, and capillary invasion

2.1.6.1 Cancer stromal volume (to be recorded for T1b or deeper tumors)

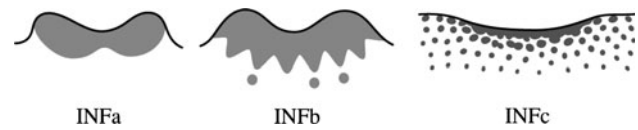
Medullary type (med): Scanty stroma
 Scirrhous type (sci): Abundant stroma
 Intermediate type (int): The quantity of stroma is intermediate between the two above types.

2.1.6.2 Tumor infiltrative (INF) pattern into the surrounding tissues (to be recorded in T1b or deeper tumors; Fig. 5)

INFa Tumor displays expanding growth with a distinct border from the surrounding tissue
 INFb Tumor shows an intermediate pattern between INFa and INFc
 INFc Tumor displays infiltrative growth with no distinct border with the surrounding tissue.

² Tumor extending into the greater or lesser omentum without visceral peritoneal perforation is classified as T3.

³ Invaded adjacent structures should be recorded. The adjacent structures of the stomach are the liver, pancreas, transverse colon, spleen, diaphragm, abdominal wall, adrenal gland, kidney, small intestine, and retroperitoneum. Serosal invasion with involvement of the greater and lesser omentum is classified as T4a, not T4b. Invasion of the transverse mesocolon is not T4b unless it extends to the colic vessels or penetrates the posterior surface of the mesocolon.

**Fig. 5** Tumor infiltrative (INF) pattern

2.1.6.3 Capillary invasion⁴

2.1.6.3.1 Lymphatic invasion (ly)

ly0: No lymphatic invasion
 ly1: Minimal lymphatic invasion
 ly2: Moderate lymphatic invasion
 ly3: Marked lymphatic invasion

2.1.6.3.2 Venous invasion (v)

v0: No venous invasion
 v1: Minimal venous invasion
 v2: Moderate venous invasion
 v3: Marked venous invasion

2.2 Lymph node metastasis

2.2.1 Anatomical definition of lymph nodes and lymph node regions (Figs. 6, 7)

The lymph nodes (LNs) of the stomach are defined and given station numbers, as shown in Table 5 and Figs. 7, 8, 9. Lymph node stations 1–12 and 14v are defined as regional gastric lymph nodes; metastasis to any other nodes is classified as M1. In tumors invading the esophagus, lymph node numbers 19, 20, 110, and 111 are included as regional lymph nodes. For carcinomas arising in the remnant stomach with a gastrojejunostomy, jejunal lymph nodes adjacent to the anastomosis are included as regional lymph nodes. Please refer to the “Gastric Cancer Treatment Guidelines” [1] for a detailed account of which lymph nodes are to be dissected in gastric resection with curative intent.

2.2.2 Recording of lymph node metastasis

For surgical resection specimens, the total number of lymph nodes and the number of involved lymph nodes at each nodal station are recorded. When a tumor nodule without histological evidence of lymph node structure is found in the lymphatic drainage area of the primary tumor, it is recorded as extranodal metastasis and counted as a metastatic lymph node in the pN determination.

⁴ In endoscopically resected specimens, capillary invasion is recorded as ly (–) or ly (+), and v (–) or v (+).

Fig. 6 Location of lymph node stations

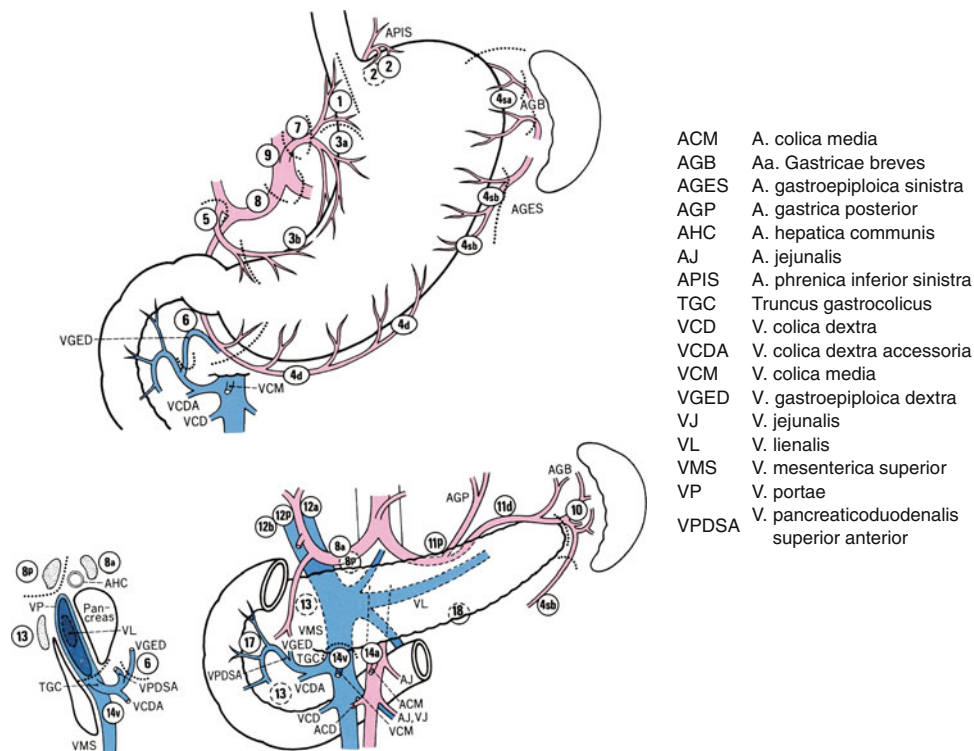
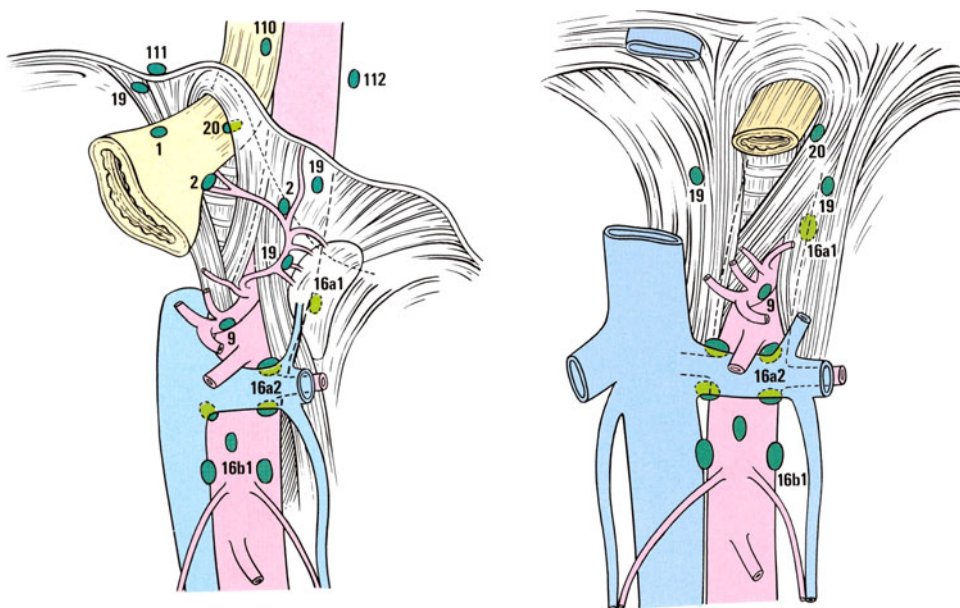


Fig. 7 Location of lymph nodes in the esophageal hiatus and in the infradiaphragmatic and paraaortic regions



2.2.2.1 Lymph node metastasis (N)

- NX: Regional lymph nodes cannot be assessed
- N0: No regional lymph node metastasis
- N1: Metastasis in 1–2 regional lymph nodes
- N2: Metastasis in 3–6 regional lymph nodes
- N3: Metastasis in 7 or more regional lymph nodes
- N3a: Metastasis in 7–15 regional lymph nodes

N3b: Metastasis in 16 or more regional lymph nodes

Although it is not a prerequisite, the examination of 16 or more regional lymph nodes is recommended for N status determination.

2.2.2.2 Metastatic ratio of lymph nodes The metastatic ratio is the ratio of metastatic nodes to the total number of

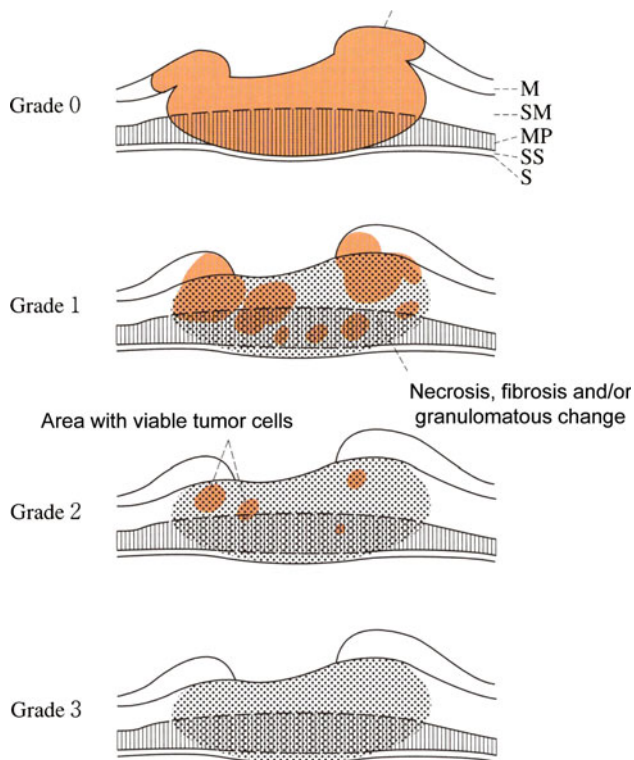


Fig. 8 Histological evaluation criteria of tumor response after preoperative therapy

dissected nodes and is recorded for each nodal station for all regional lymph nodes.

2.3 Distant metastasis

Metastasis to sites other than regional lymph nodes (distant metastasis) is M1 disease. In addition, peritoneal metastasis, peritoneal lavage cytology, and hepatic metastasis may be described by the conventional symbols P, CY, and H, respectively (see below). Positive peritoneal lavage cytology is recorded as cy+ by the International Union Against Cancer (UICC)/TNM system.

2.3.1 Presence or absence and sites of distant metastasis (M)

- MX: Distant metastasis status unknown
- M0: No distant metastasis
- M1: Distant metastasis

Sites of metastasis are recorded using the following notation: LYM (lymph nodes), SKI (skin), PUL (lung), MAR (bone marrow), OSS (bone), PLE (pleura),

BRA (brain), MEN (meninx), ADR (adrenal), OTH (others)⁵

2.3.2 Peritoneal metastasis (P)

- PX: Peritoneal metastasis is unknown
- P0: No peritoneal metastasis
- P1: Peritoneal metastasis.

2.3.3 Peritoneal lavage cytology (CY)

- CYX: Peritoneal cytology not performed
- CY0: Peritoneal cytology negative for carcinoma cells
- CY1: Peritoneal cytology positive for carcinoma cells

A macroscopically curative resection with CY1 is R1.

2.3.4 Hepatic metastasis (H)

- HX: Hepatic metastasis is unknown
- H0: No hepatic metastasis
- H1: Hepatic metastasis.

2.4 Stage grouping

	N0	N1	N2	N3
T1a (M), T1b (SM)	IA	IB	IIA	IIB
T2 (MP)	IB	IIA	IIB	IIIA
T3 (SS)	IIA	IIB	IIIA	IIIB
T4a (SE)	IIB	IIIA	IIIB	IIIC
T4b (SI)	IIIB	IIIB	IIIC	IIIC
M1 (Any T, Any N)	IV			

⁵ Other sites include retroperitoneal carcinomatosis and the ovaries (Krukenberg).

3 Treatment evaluation

3.1 Evaluation after surgical or endoscopic resection

3.1.1 Surgical specimen resection margin

3.1.1.1 Proximal margin (PM)

- PMX Involvement of the proximal margin cannot be assessed
 PM0 No involvement of the proximal margin
 PM1 Involvement of the proximal margin.

3.1.1.2 Distal margin (DM)

- DMX Involvement of the distal margin cannot be assessed
 DM0 No involvement of the distal margin
 DM1 Involvement of the distal margin.

3.1.2 Resection margin of the endoscopic resection specimen

3.1.2.1 Horizontal margin (HM)

- HMX Involvement of the horizontal margin cannot be assessed
 HM0 No involvement of the horizontal margin
 HM1 Involvement of the horizontal margin.

3.1.2.2 Vertical margin (VM)

- VMX Involvement of the vertical margin cannot be assessed
 VM0 No involvement of the vertical margin
 VM1 Involvement of the vertical margin.

3.1.3 Residual tumor (R)

The presence or absence of residual tumor after surgery is described as the R status; R0 is a curative resection with negative resection margins; R1 and R2 are non-curative resections.

- RX Presence of residual tumor cannot be assessed
 R0 No residual tumor
 R1 Microscopic residual tumor (positive resection margin or CY1)
 R2 Macroscopic residual tumor.

3.2 Tumor evaluation after preoperative treatment

3.2.1 Description of tumor classification after preoperative treatment

Tumor classification after preoperative chemotherapy or chemoradiotherapy is designated by the prefix 'y'. The

clinical classification following preoperative treatment is designated ycTNM and the pathological classification ypTNM. The ycTNM and ypTNM classification describes the extent of tumor actually present at the time of that examination; it is not an estimate of the extent of tumor prior to preoperative therapy. Only viable tumor cells are taken into account when calculating ypTNM. Signs of tumor regression, including scars, areas of fibrosis, granulation tissue, or mucin lakes are not taken into consideration.

For example: A large adenocarcinoma with computed tomography (CT) evidence of serosal irregularity and lymph node metastasis was classified as cT4aN1M0. Preoperative chemotherapy achieved significant tumor regression, with the tumor being undetectable by endoscopy and CT (ycT0N0M0). Gastrectomy was performed and histological examination revealed viable carcinoma cells in the muscularis propria and in two regional lymph nodes; granulation tissue with mucin lakes was present in five other lymph nodes (ypT2N1M0).

3.2.2 Histological evaluation criteria of tumor response after preoperative therapy (Fig. 8)

The histological response of the primary tumor should be evaluated in the section where the tumor is thought to have been located at the pretreatment assessment and in the sections where tumor cells are likely to remain. Viable tumor cells are defined as cells which are judged to be capable of proliferation.

Grade 0 (no effect)	No evidence of effect
Grade 1 (slight effect)	
Grade 1a (very slight effect)	Viable tumor cells occupy more than 2/3 of the tumorous area
Grade 1b (slight effect)	Viable tumor cells remain in more than 1/3 but less than 2/3 of the tumorous area
Grade 2 (considerable effect)	Viable tumor cells remain in less than 1/3 of the tumorous area
Grade 3 (complete response)	No viable tumor cells remain. It is recommended that the finding is confirmed on additional sectioning.

3.3 Response evaluation of chemotherapy and radiotherapy

Tumor response to chemotherapy and/or radiotherapy is assessed using the Response Evaluation Criteria in Solid Tumors (RECIST) version 1.1 [2].

The Japanese Gastric Cancer Association (JGCA) developed an original method to evaluate the response of the primary gastric lesion to chemotherapy or radiotherapy [3], but it was not widely used, mainly because of technical difficulties. In the RECIST, primary gastric tumors are regarded as non-target lesions and endoscopic diagnosis is not recommended as an objective evaluation. However, the response of the primary tumor is clinically important and the JGCA methods may provide useful information in future neoadjuvant trials. The results of response evaluation of the primary tumor made by the following methods can be recorded and used as information that is additional to the RECIST results in some trial settings.

3.3.1 JGCA response evaluation of primary tumor

Tumor response, morphological changes, and efficacy are evaluated by double-contrast barium meal study and/or endoscopic examination of the following three types of primary lesions.

3.3.1.1 Measurable lesions (a-lesions) Reduction rate = (longest diameter before therapy – longest diameter after therapy)/longest diameter before therapy.

3.3.1.2 Evaluable but not measurable lesions (b-lesions)

(i) Describe changes in protruded lesions as follows: Progression, no change, regression, flattening, or disappearance

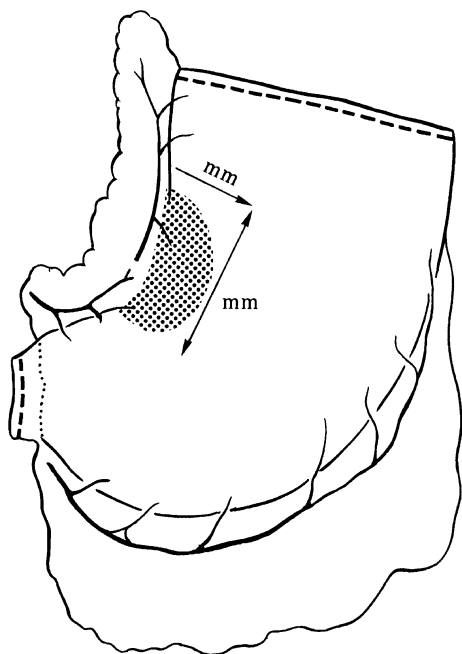


Fig. 9 Measurement of the lesion from the serosal surface

(ii) Describe changes in excavated lesions as follows:

- Raised margin: progression, no change, regression, flattening, or disappearance
- Crater: progression, no change, regression, flattening, or disappearance.

3.3.1.3 Diffusely infiltrating lesions (c-lesions) [3] In diffusely infiltrating tumors (type 4), treatment response may be evaluated by expansion of the gastric lumen. In principle, the squares of the lesion shown with standing barium X-ray examination are compared before and after therapy, at the same position with the same volume of barium, and the enlargement rate is calculated.

Enlargement rate = (product calculated before therapy) – (product calculated after therapy)/(product calculated before therapy) × 100%

3.3.1.4 Definition of response in primary lesion

- Complete response (CR)
Disappearance of all tumor lesions and no diagnosis of carcinoma. Biopsy specimens are negative for carcinoma.
- Partial response (PR)

a-lesions: At least a 30% decrease in total size

b-lesions: Remarkable regression and flattening of a tumor on X-ray/endoscopic examinations, which roughly corresponds to at least a 50% decrease in tumor size.

c-lesions: At least 50% enlargement of the gastric lumen in the area of the lesions by X-ray examination.

- Stable disease (SD)
Changes in tumor size or shape are less than PR, but are not progressive disease (PD).

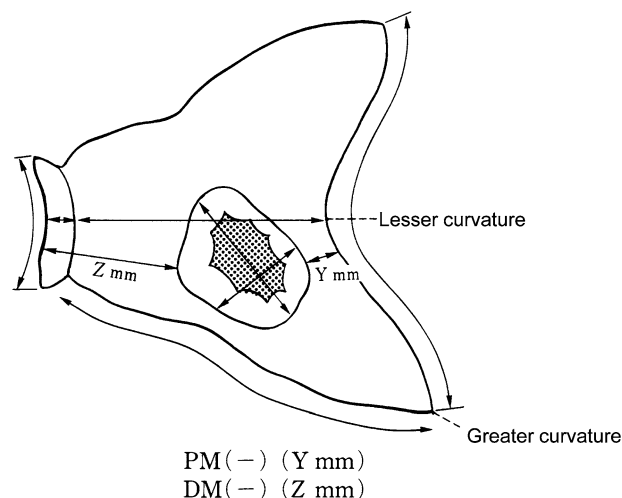


Fig. 10 Measurement of the lesion from the mucosal surface. *PM* proximal margin, *DM* distal margin

- Progressive disease (PD)
Increase in tumor size and/or worsening of the shape (20% or more increase in a-lesions), or new intragastric lesions.

4 Handling of the resected specimen

4.1 Description of findings

Pathological findings are recorded when the following conditions are met.

- The whole resected stomach is macroscopically observed.
- The representative sections of the whole resected stomach including the carcinoma are microscopically examined.

4.2 Preparation of the resected stomach

After gross inspection and measurement of any serosal tumor involvement (Fig. 9), the stomach is, in principle, opened along the greater curvature. On examination from the mucosal side, the tumor size and the length of the proximal and distal resection margins are measured (Fig. 10).

4.3 Fixation of the resected stomach

After dissection of the lymph nodes from the specimen, the stomach is placed on a flat board with the mucosal side up, pinned at the edges with stainless steel pins, and fixed in a 10% buffered formalin solution. A relatively short fixation time (48 h) is recommended for additional immunohistochemical or genetic examinations in the future.

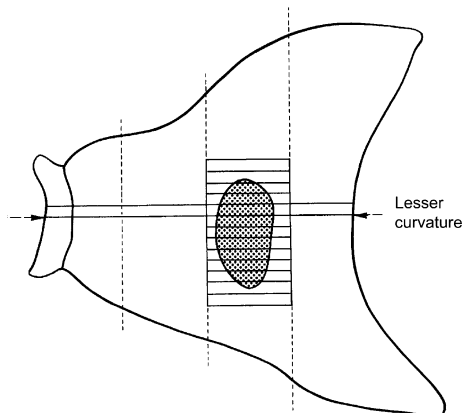


Fig. 11 Sectioning of Type 0 superficial tumors

4.4 Sectioning of the stomach

Firstly a section is taken along the lesser curvature as a reference line to assess background mucosal changes. In Type 0 superficial tumors, a set of sections parallel to the reference line should be made at 5- to 7-mm intervals (Fig. 11). In advanced tumors, the area of deepest invasion should be sectioned parallel to the reference line. If there is concern about tumor margins, additional sections should be taken (Fig. 12). In multiple tumors or tumors of unusual configuration, suitable sectioning to obtain accurate findings must be devised on a case-by-case basis. The carcinoma in a remnant stomach should be sectioned taking into account its relationship with the suture line and anastomosis.

4.5 Sectioning of lymph nodes

Each dissected lymph node should be studied individually. The plane of largest dimension of the node including the hilus should be sectioned.

4.6 Handling of endoscopically resected specimens

A single resection procedure performed for a single lesion is defined as “en-bloc resection”, and multiple resection procedures for a single lesion are defined as “piecemeal resection”.

4.6.1 Fixation, inspection, and sectioning

The specimen is spread out, pinned on a flat board, and fixed in 10% buffered formalin solution. The size of the

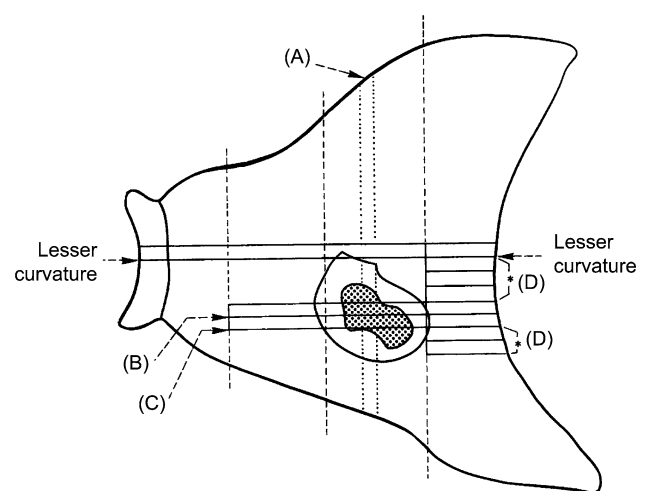


Fig. 12 Sectioning of advanced tumors. *A* Additional sectioning for decision on T-category. *B* Sectioning of the largest cross-sectional plane. *C* Sectioning of the region of deepest invasion. *D* Sectioning to examine the proximal margin

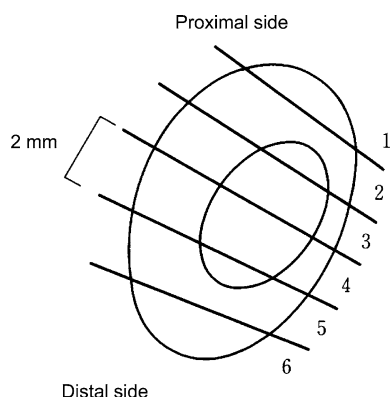


Fig. 13 Sectioning of endoscopic resection material

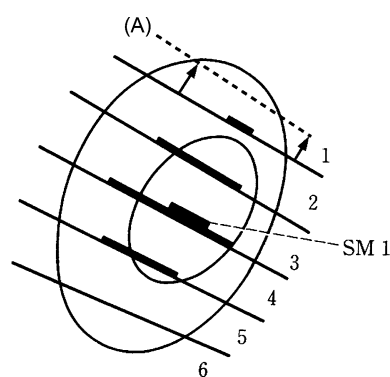


Fig. 14 Rebuilt diagram of endoscopic resection material. The cancerous area is marked with a *thick line*. *SM1* submucosal invasion. *A* Additional sectioning to examine the true margin

specimen, the size and shape of the tumor, and the margins should be recorded on a schematic diagram. The proximal and distal margins are indicated. Fixed materials should be sectioned serially at 2-mm intervals parallel to a line that includes the closest resection margin of the specimen (Fig. 13). When resection margin involvement cannot be denied on a rebuilt diagram such as that shown in Fig. 14, sectioning should be added to examine the true margin.

4.6.2 Histological diagnosis

The following should be recorded.

- The size and number of specimens
- Macroscopic type of the tumor
- The size of the tumor (longest and shortest diameters)
- Histological type of the tumor
 - Different histological types seen in a tumor are recorded according to their quantitative predominance
- Depth of tumor invasion (pT1a, pT1b1, pT1b2 or M, SM1, SM2)

Depth is determined and recorded only when the vertical margin is negative for cancer invasion.

When submucosal invasion is present, the actual measured length (in microns) from the lower border of the muscularis mucosae should also be recorded. If the muscularis mucosae is obscure due to ulcerative changes, the length should be measured on the virtual line based on the adjacent normal layer.

When the vertical margin is involved, the possibility of deeper invasion should be described.

- Intratumoral ulcerative findings
 - UL(-): Ulcer or ulcer scar is absent
 - UL(+): Ulcer or ulcer scar is present.
- Capillary invasion
 - ly(-): Lymphatic invasion is absent
 - ly(+): Lymphatic invasion is present
 - v(-): Venous invasion is absent
 - v(+): Venous invasion is present.
- Horizontal margin involvement
 - HMX: Horizontal margin involvement is unknown
 - HM0: Horizontal margin is not involved (The length of the margin should be recorded)
 - HM1: Horizontal margin is involved (The number of positive sections should be recorded).
- Vertical margin involvement
 - VMX: Vertical margin involvement is unknown
 - VM0: Vertical margin is not involved
 - VM1: Vertical margin is involved.

4.7 Histological diagnosis of gastric biopsy (“Group Classification”)

4.7.1 Principles

This classification is applied only to endoscopic biopsy materials. Materials obtained by polypectomy, endoscopic resection, or surgery are not included. The “Group Classification” is applied only to epithelial tissue. In principle, the diagnosis is written first, followed by the Group Classification.

4.7.2 Classification

- Group X Inappropriate material for which histological diagnosis cannot be made
- Group 1 Normal tissue or non-neoplastic lesion

Group 2 Material for which diagnosis of neoplastic or non-neoplastic lesion is difficult
In such a case, the pathologist should describe the lesion as “indefinite for neoplasia” and add the following reasons for clinicians:

- (1) Atypical cells exist, but diagnosis of neoplasia based on cellular atypia is difficult because of the small volume.
- (2) Atypical cells exist, but diagnosis of neoplastic or non-neoplastic lesion is difficult due to remarkable erosion and/or inflammation.
- (3) Atypical cells exist, but diagnosis of neoplastic or non-neoplastic lesion is difficult due to tissue damage.

Group 3 Adenoma

Group 4 Neoplastic lesion that is suspected to be carcinoma

Group 5 Carcinoma

The histological subtype of carcinoma should be recorded.

References

1. Japanese Gastric Cancer Association. Japanese gastric cancer treatment guidelines 2010 (ver. 3). *Gastric Cancer* 2011. doi: [10.1007/s10120-011-0042-4](https://doi.org/10.1007/s10120-011-0042-4).
2. Eisenhauer EA, Therasse P, Bogaerts J, et al. New response evaluation criteria in solid tumours: Revised RECIST guideline (version 1.1). *Eur J Cancer*. 2009;45:228–47.
3. Japanese Gastric Cancer Association. Japanese Classification of Gastric Carcinoma–2nd English Edition–Response assessment of chemotherapy and radiotherapy for gastric carcinoma: clinical criteria. *Gastric Cancer*. 2001;4:1–8.